ΔΙΑΓΝΩΣΗ ΚΑΙ ΑΝΤΙΜΕΤΩΠΙΣΗ ΤΗΣ ΝΕΥΡΟΑΙΣΘΗΤΗΡΙΟΥ ΒΑΡΗΚΟΙΑΣ ΣΤΑ ΠΑΙΔΙΑ



ΘΩΜΑΣ Π. ΝΙΚΟΛΟΠΟΥΛΟΣ, MD, DM, PhD

ΚΑΘΗΓΗΤΗΣ, ΠΑΝΕΠΙΣΤΗΜΙΟ ΑΘΗΝΑΣ

ΑΤΤΙΚΟ ΝΟΣΟΚΟΜΕΙΟ

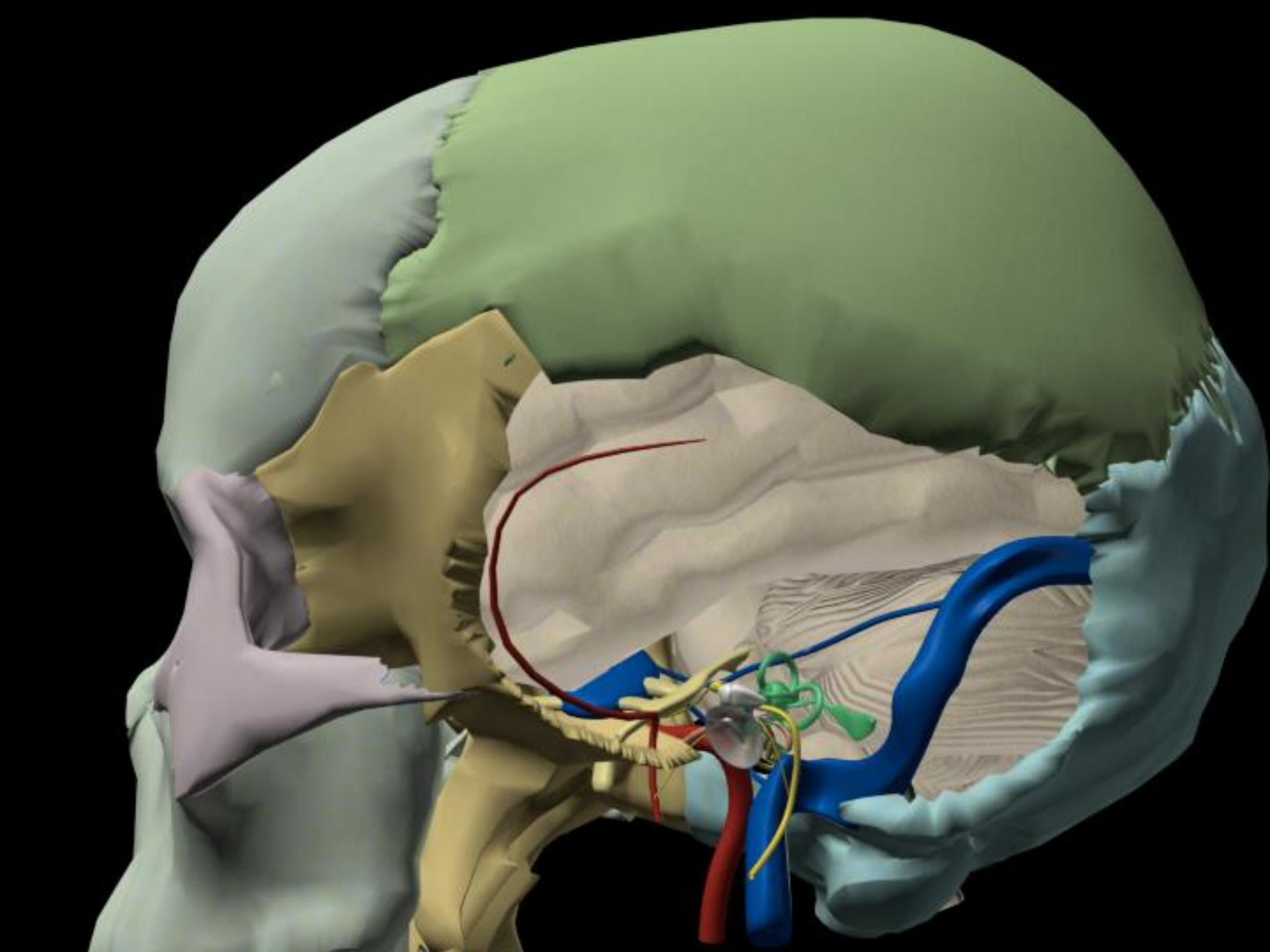

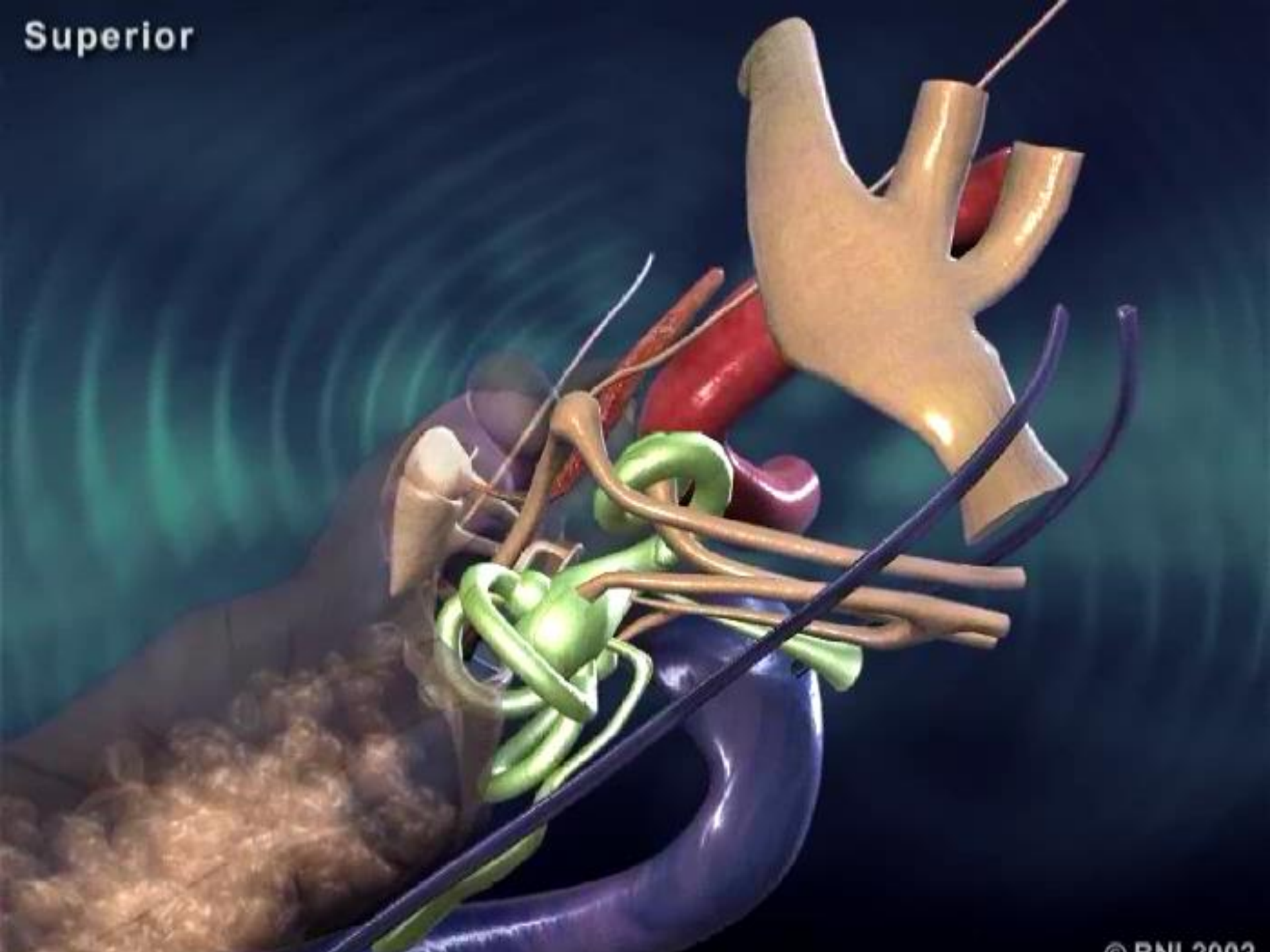
Superior
© BNI 2002

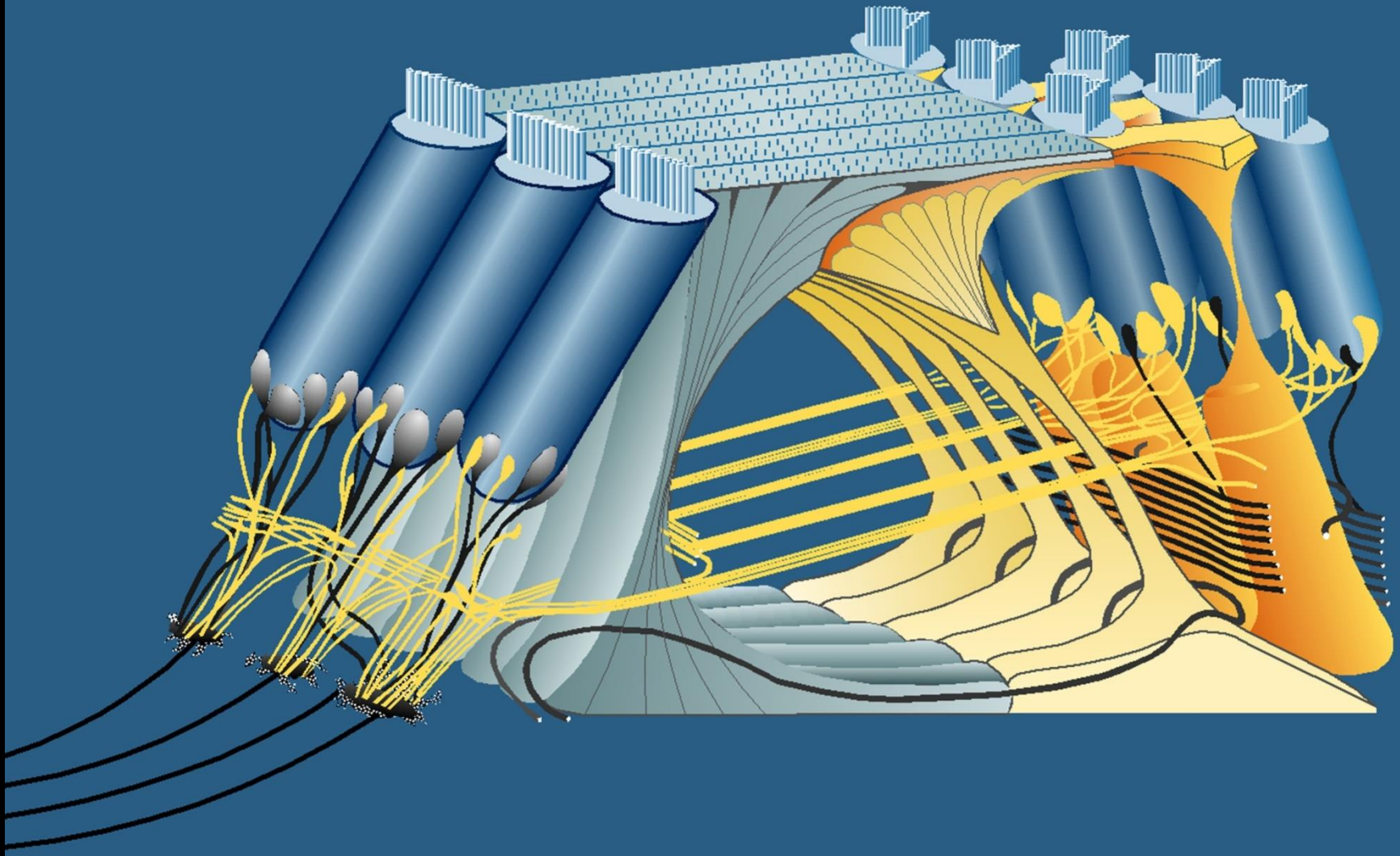



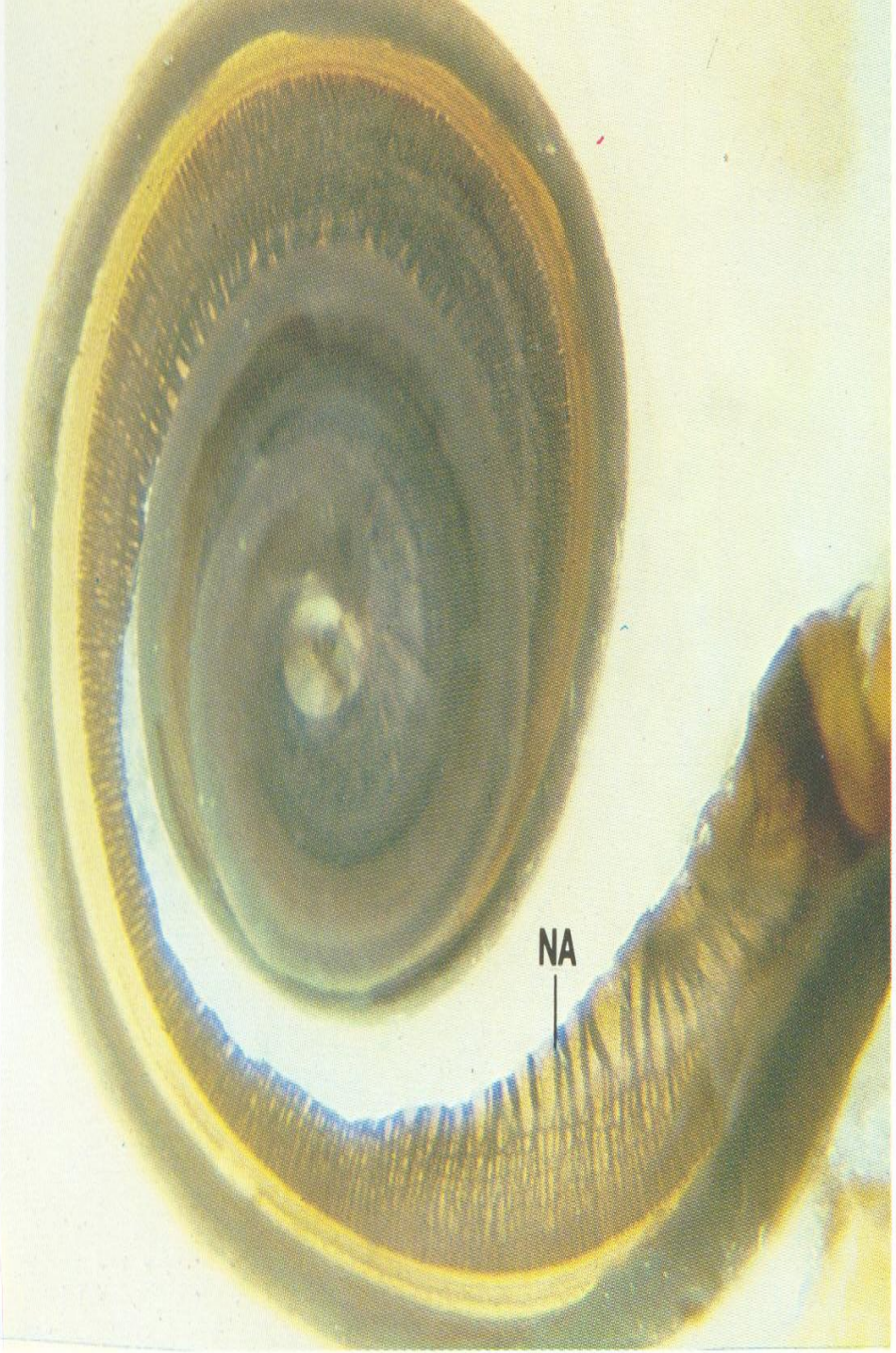

82

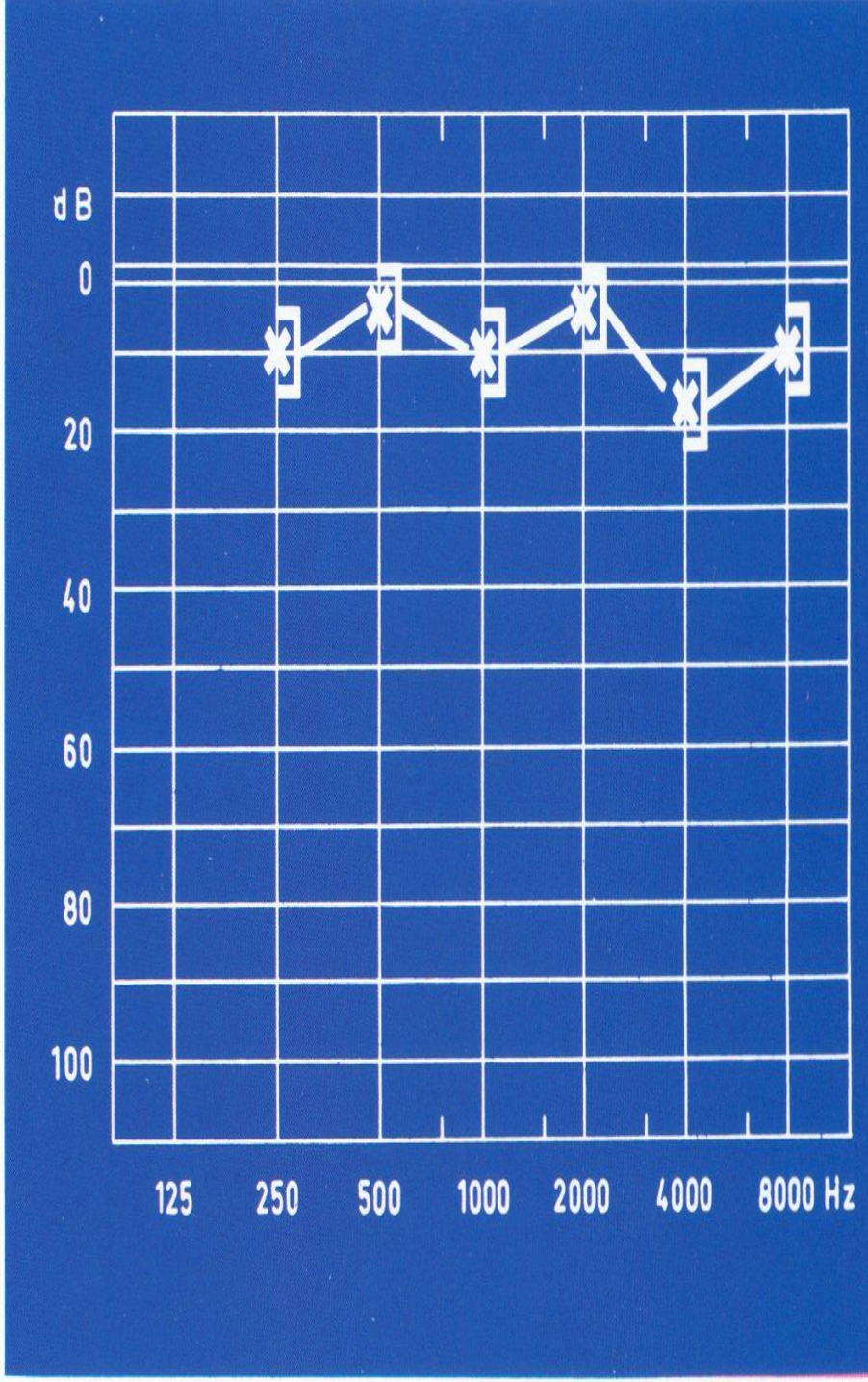

83

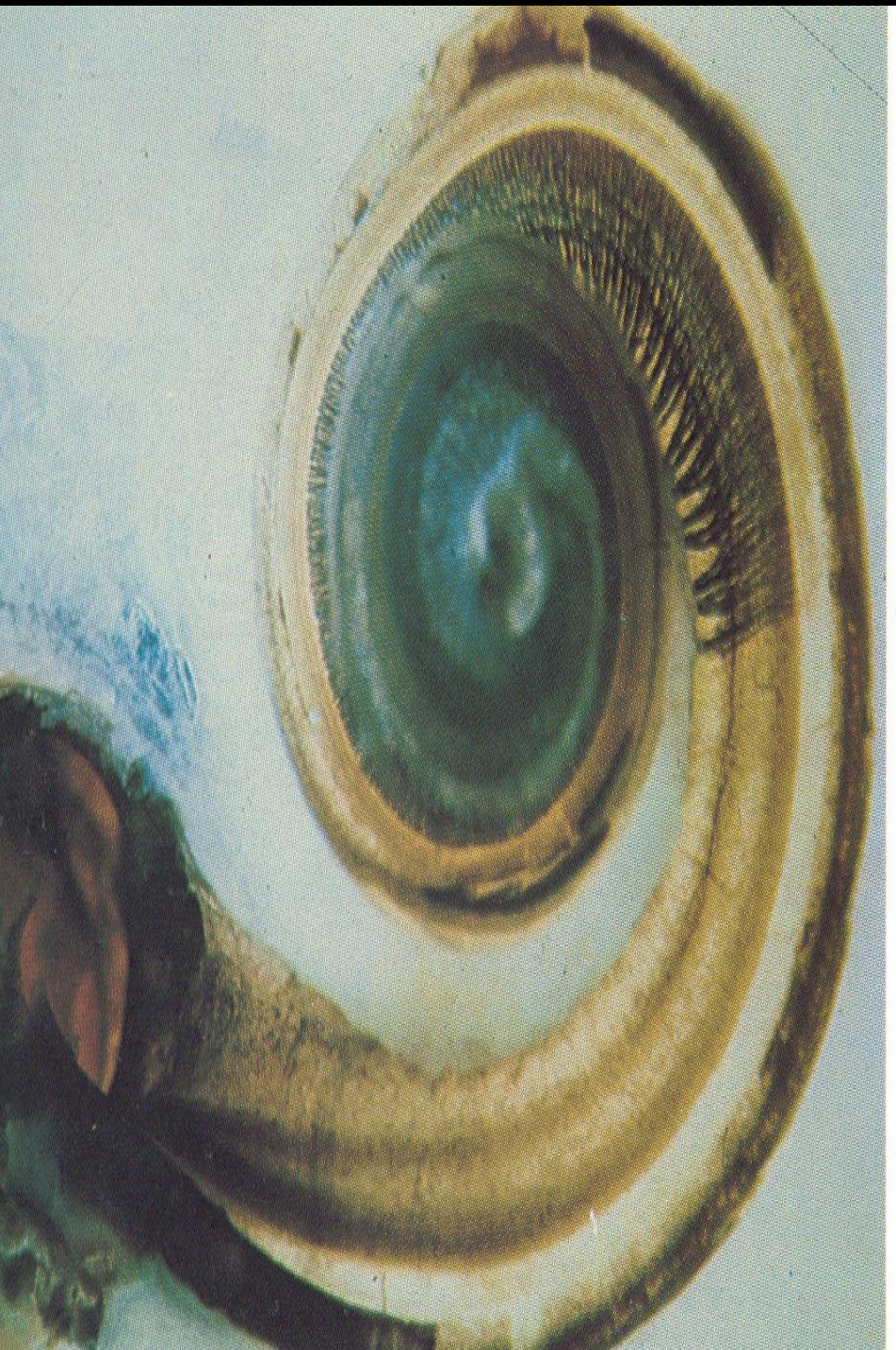

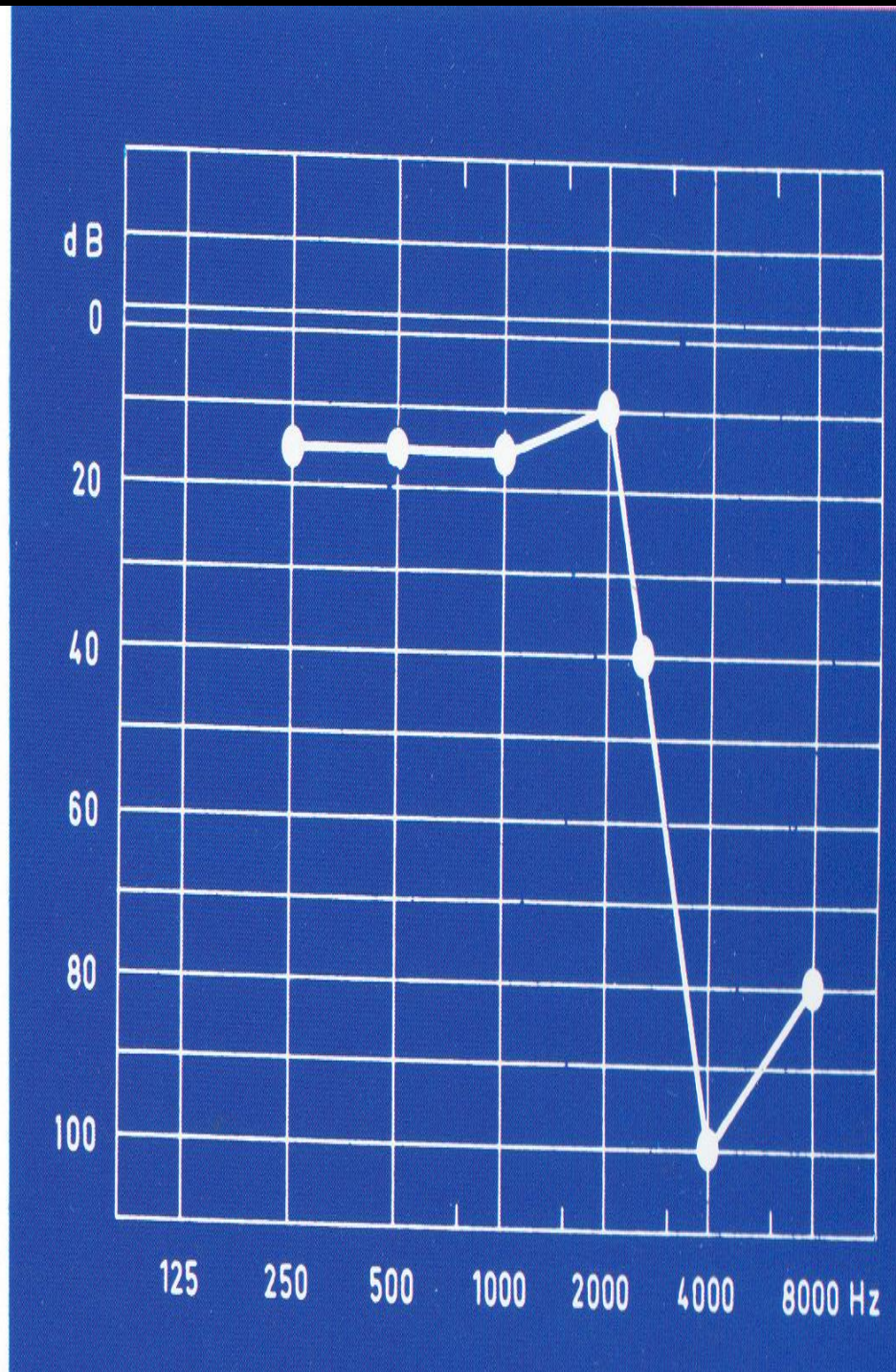
dB
0
20
40
60
80
100
125
250
500
1000
2000
4000
8000 Hz

Μπορουμε να ανιχνευσουμε την κωφωση στα νεογεννητα?

fMRI
Ανθρωπινο εμβρυο

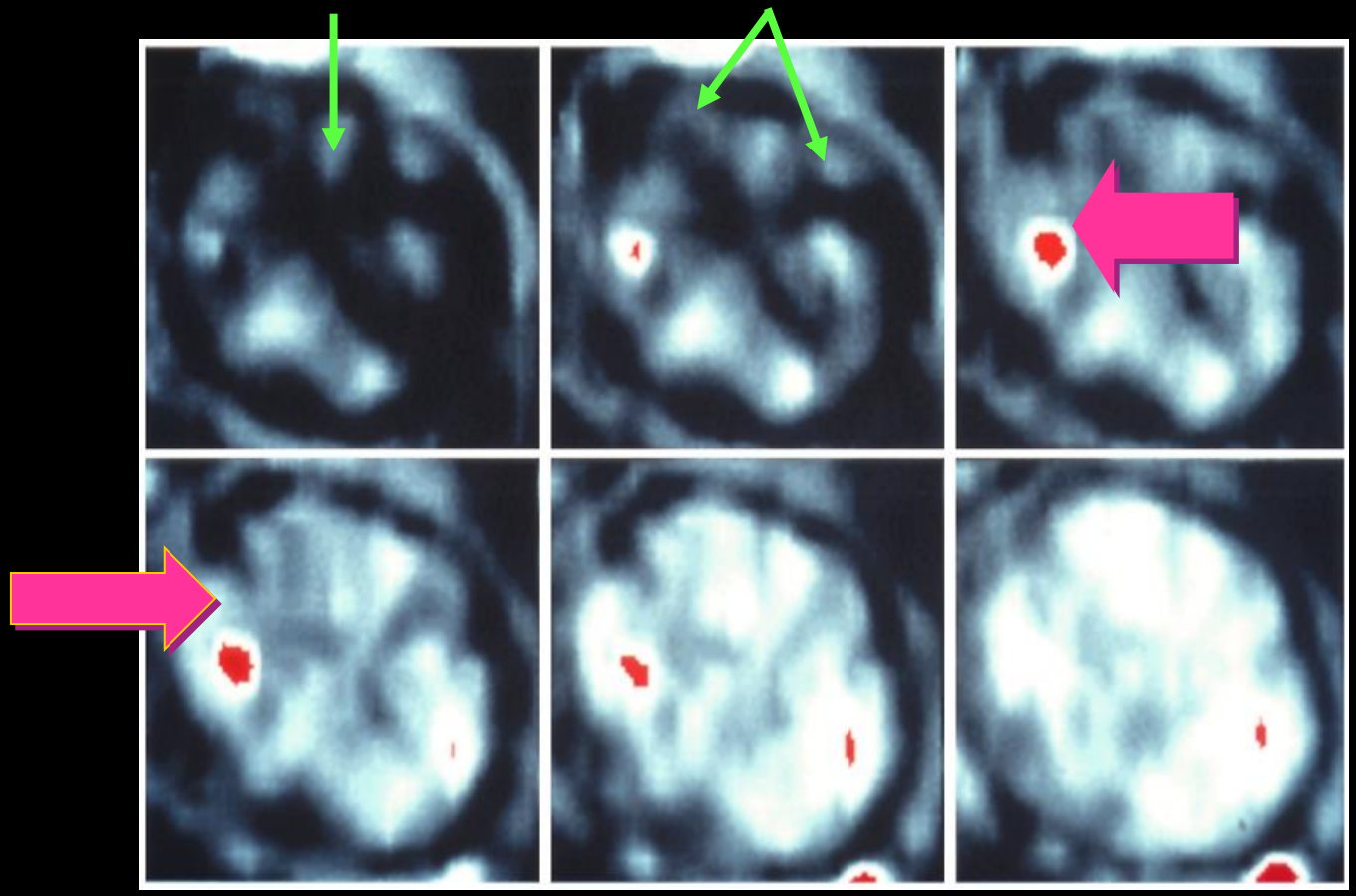

Hykin et al Lancet

Μπορουμε να ανιχνευσουμε την κωφωση στα νεογεννητα?

- Ναι.

- Με Προκλητα δυναμικα – ASSR
- Ωτοακουστικες εκπομπες

ΠΡΟΓΡΑΜΜΑ ΠΡΩΙΜΗΣ ΑΝΙΧΝΕΥΣΗΣ ΒΑΡΗΚΟΙΑΣ ΣΤΑ ΝΕΟΓΝΑ ΣΤΗΝ ΕΛΛΑΔΑ

- 25.288 νεογνά
- 23123 (98%) εκπομπές ΚΦ
- 1714 νεογνά ΜΕΘ
- 1590 (93%) εκπομπες ΚΦ
- Υψηλού ρίσκου 88% ΚΦ

ΠΡΟΓΡΑΜΜΑ ΠΡΩΙΜΗΣ ΑΝΙΧΝΕΥΣΗΣ ΒΑΡΗΚΟΙΑΣ ΣΤΑ ΝΕΟΓΝΑ ΣΤΗΝ ΕΛΛΑΔΑ

- 76560 νεογνά
- 74996 (98%) εκπομπές ΚΦ
- 1564 (2%) εκπομπες παθολογικες
- 155 ελεγχθησαν
- 56 (36%) βαρηκοια

ΕΝΔΕΙΞΕΙΣ

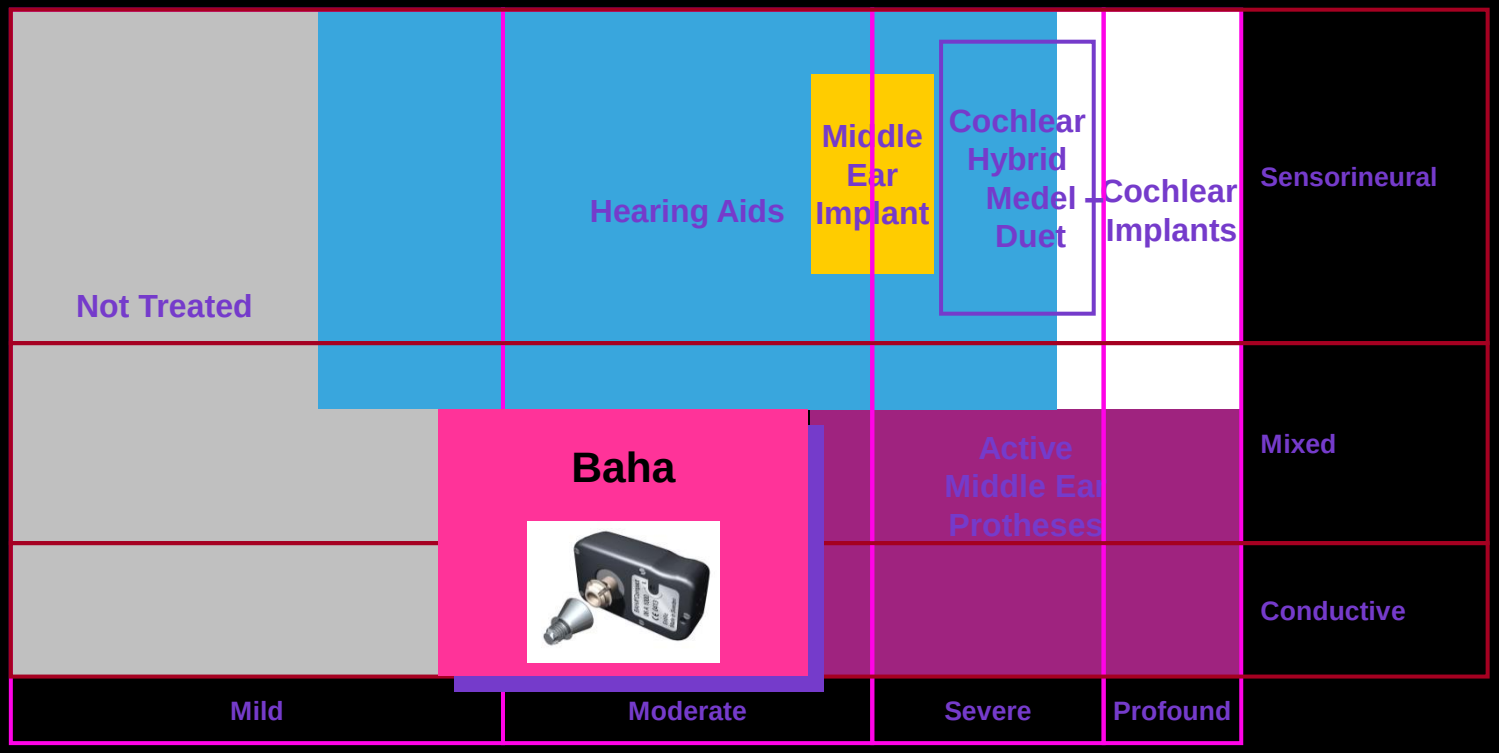
Not Treated
Hearing Aids
Middle Ear Implant
Cochlear Hybrid Medel Duet
Cochlear Implants
Sensorineural
Baha
Active Middle Ear Protheses
Mixed
Conductive
Mild
Moderate
Severe
Profound

ΑΚΟΟΛΟΓΙΚΑ ΚΡΙΤΗΡΙΑ

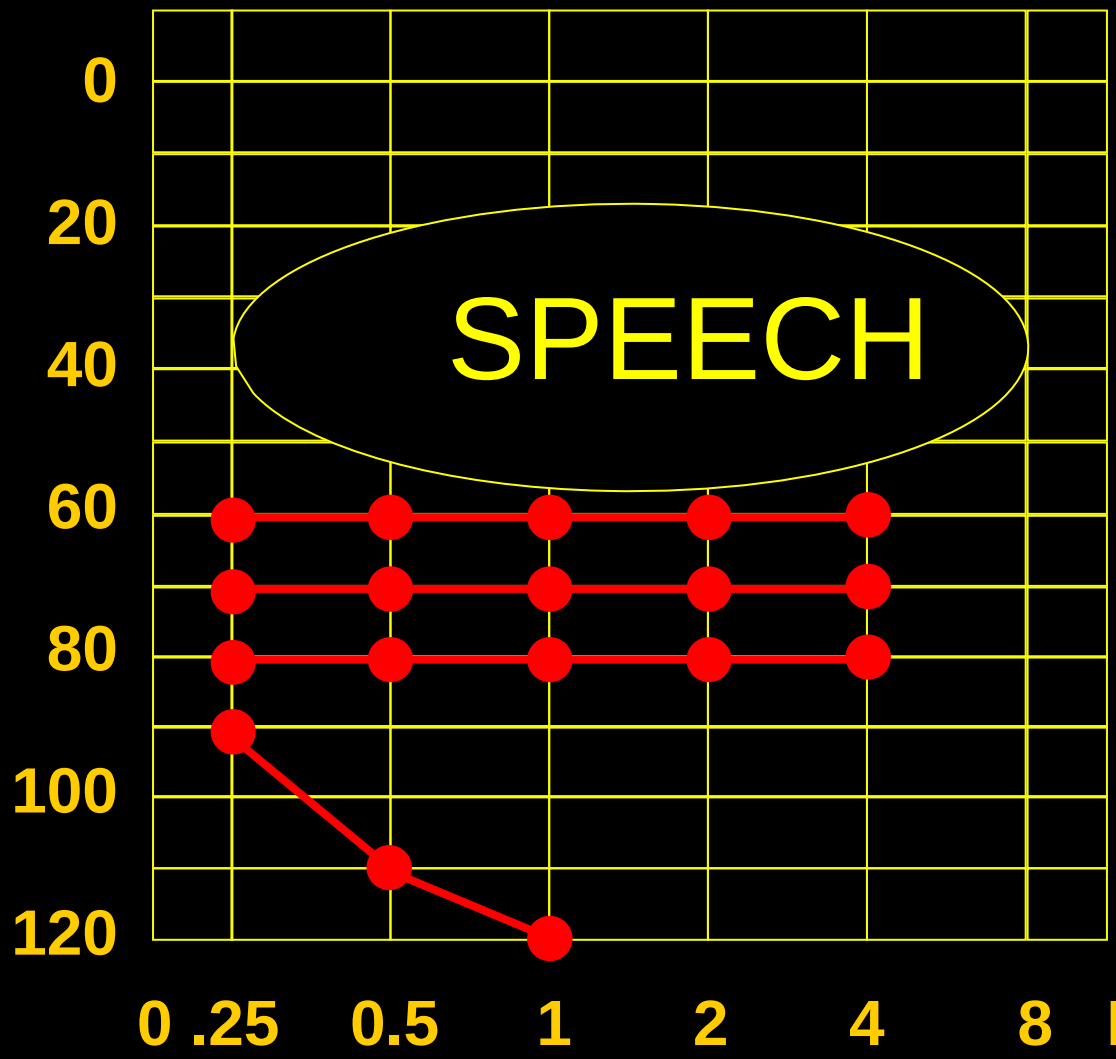





ΚΡΙΤΗΡΙΑ FDA Η.Π.Α.

	1985	1990	1998	2000
Age	Adults	Adults Children (2yrs)	Adults Children (18 mo)	**Adults** **Children (12 mo)**
Onset of sev.-prof. HL	Post-linguistic	Postlinguistic Adults Pre & Postlinguistic Children	Adults & Children Pre & Postlinguistic	**Adults & Children** **Pre & Postlinguistic**
Degree of SNHL	Profound	Profound	Severe-Profound Adults Profound Children	**2 yrs & older: Severe to Profound:** **< 2 yrs: Profound**
Adult open-set sentences	0%	0%	40% or less (CID)	**implanted ear: < 50% (HINT sentences)** **contra ear/bin < 60%.**
Pediatric speech scores	Not candidates	0% open-set	Lack of auditory progress ≤ 20% (MLNT/LNT)	**Lack of auditory progress** **< 30% (MLNT/LNT)**

ΑΚΟΥΣΤΙΚΗ ΑΝΤΙΛΗΨΗ ΜΕ ΚΟΧΛΙΑΚΟ ΕΜΦΥΤΕΥΜΑ

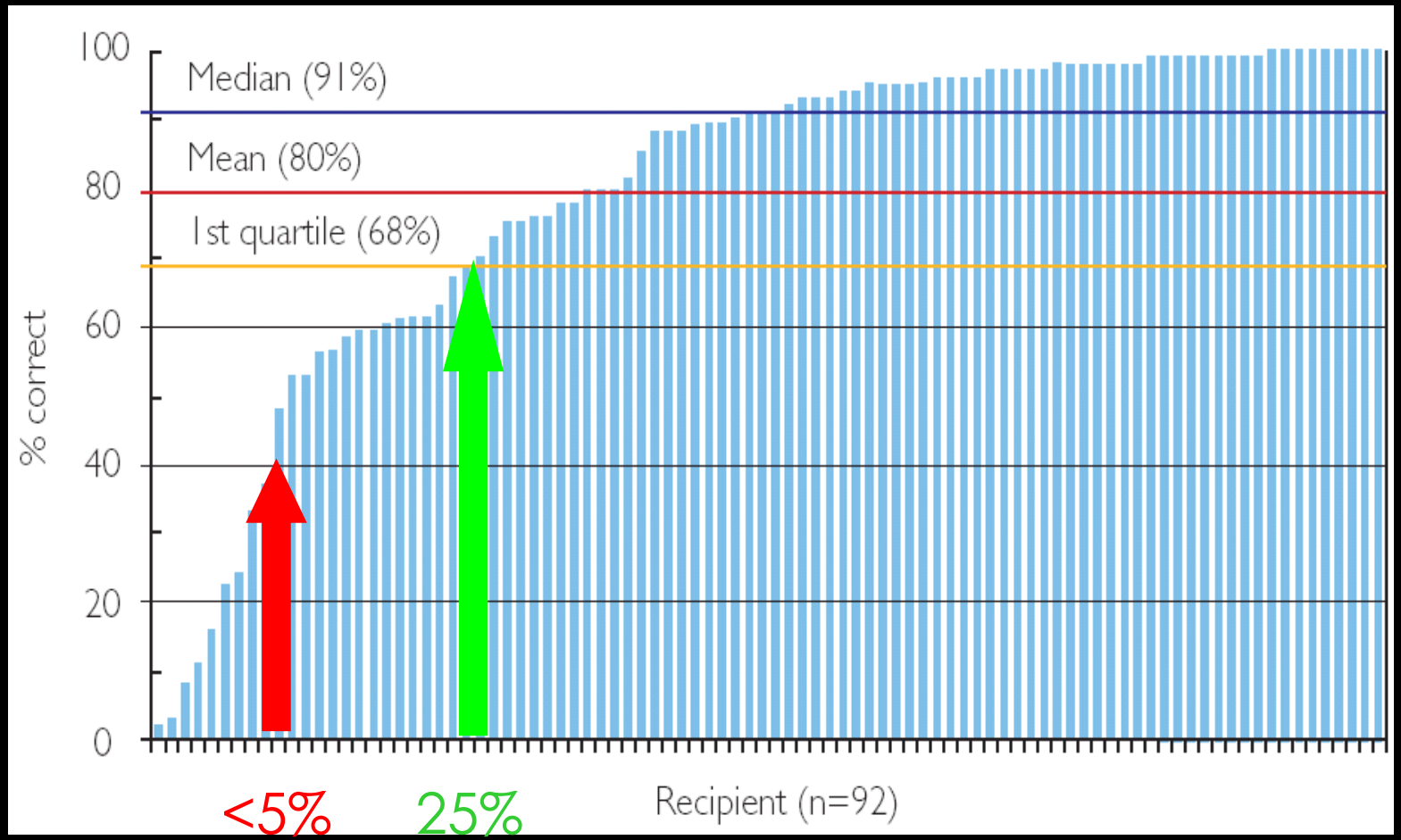

Dowell, R.C, 2004: Changing selection criteria for cochlear implants – the Melbourne experience, Cochlear N95506 ISS1, DEC03

ΕΝΔΕΙΞΕΙΣ - προβληματισμοί

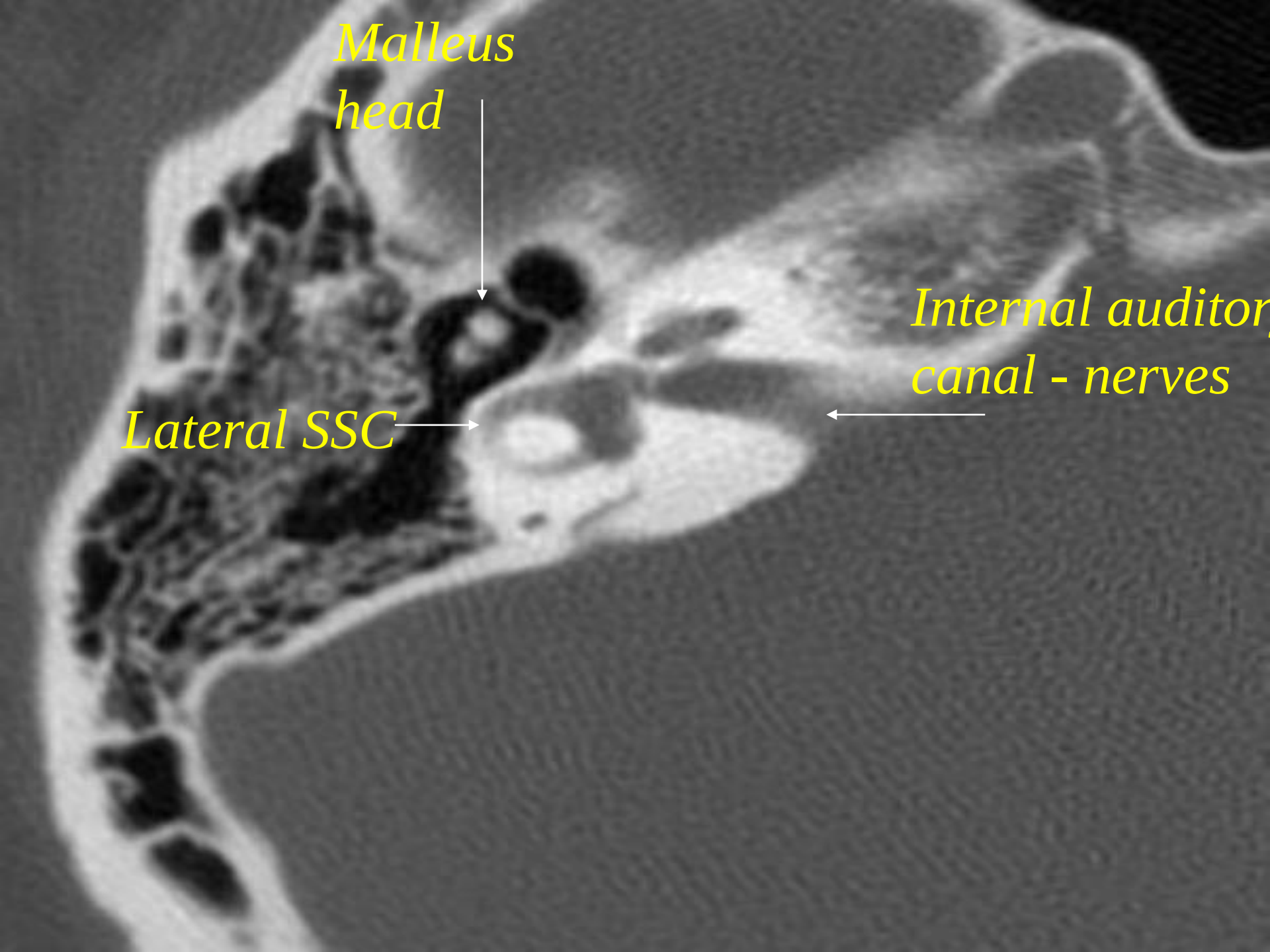
Malleus
head
Internal auditory
canal - nerves
Lateral SSC

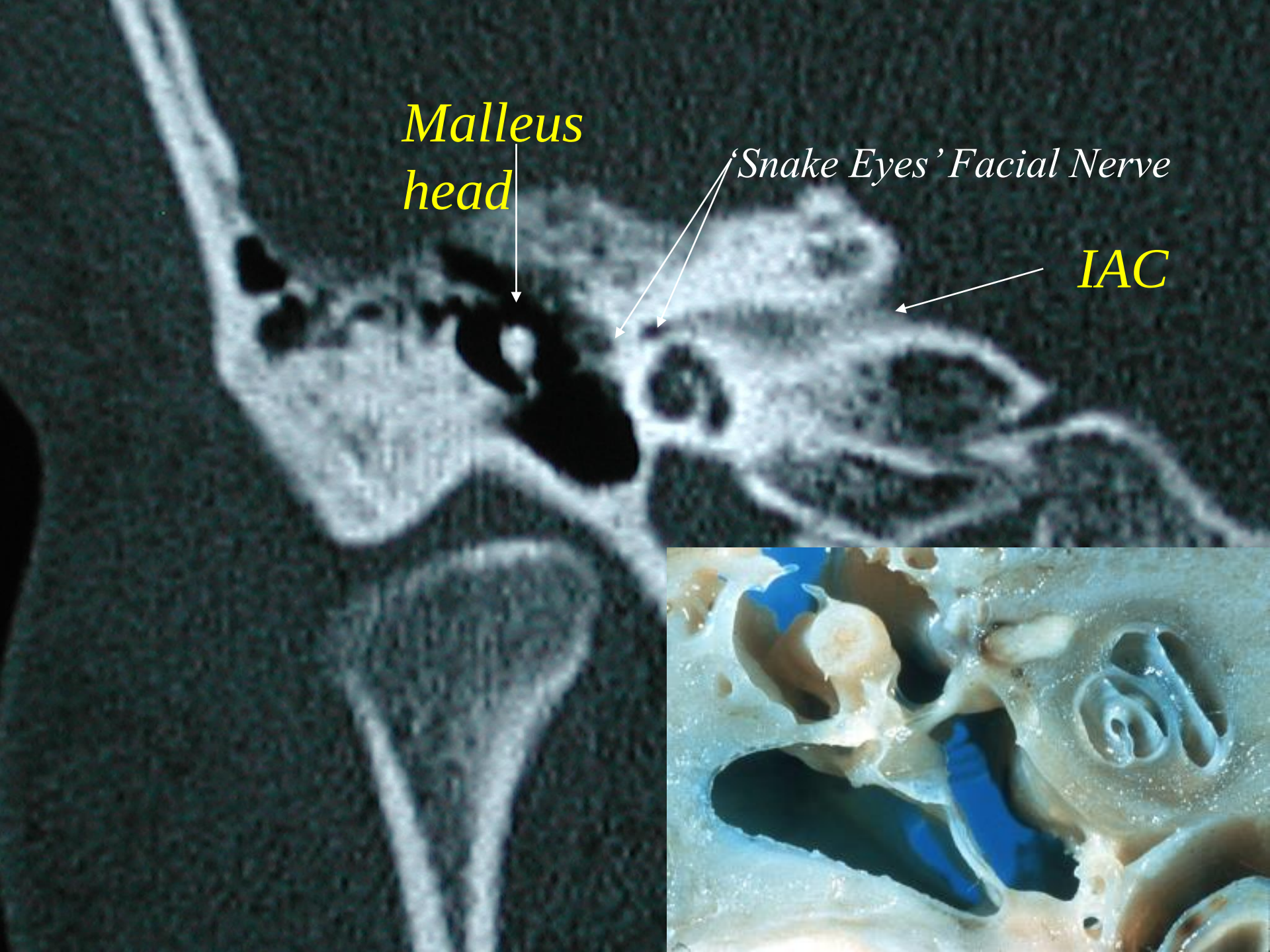
Malleus
head
'Snake Eyes' Facial Nerve
IAC

Aberrant carotid

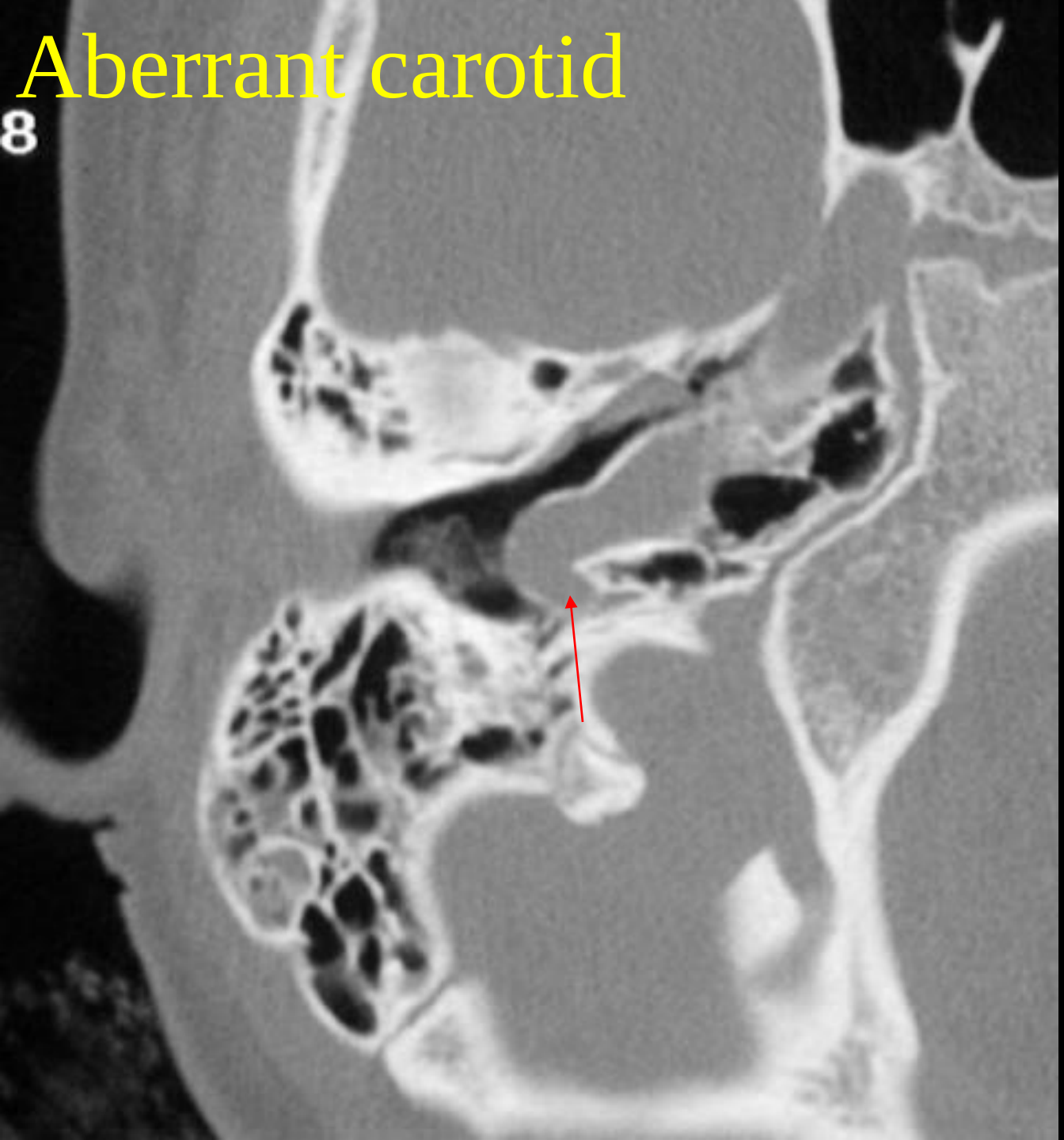

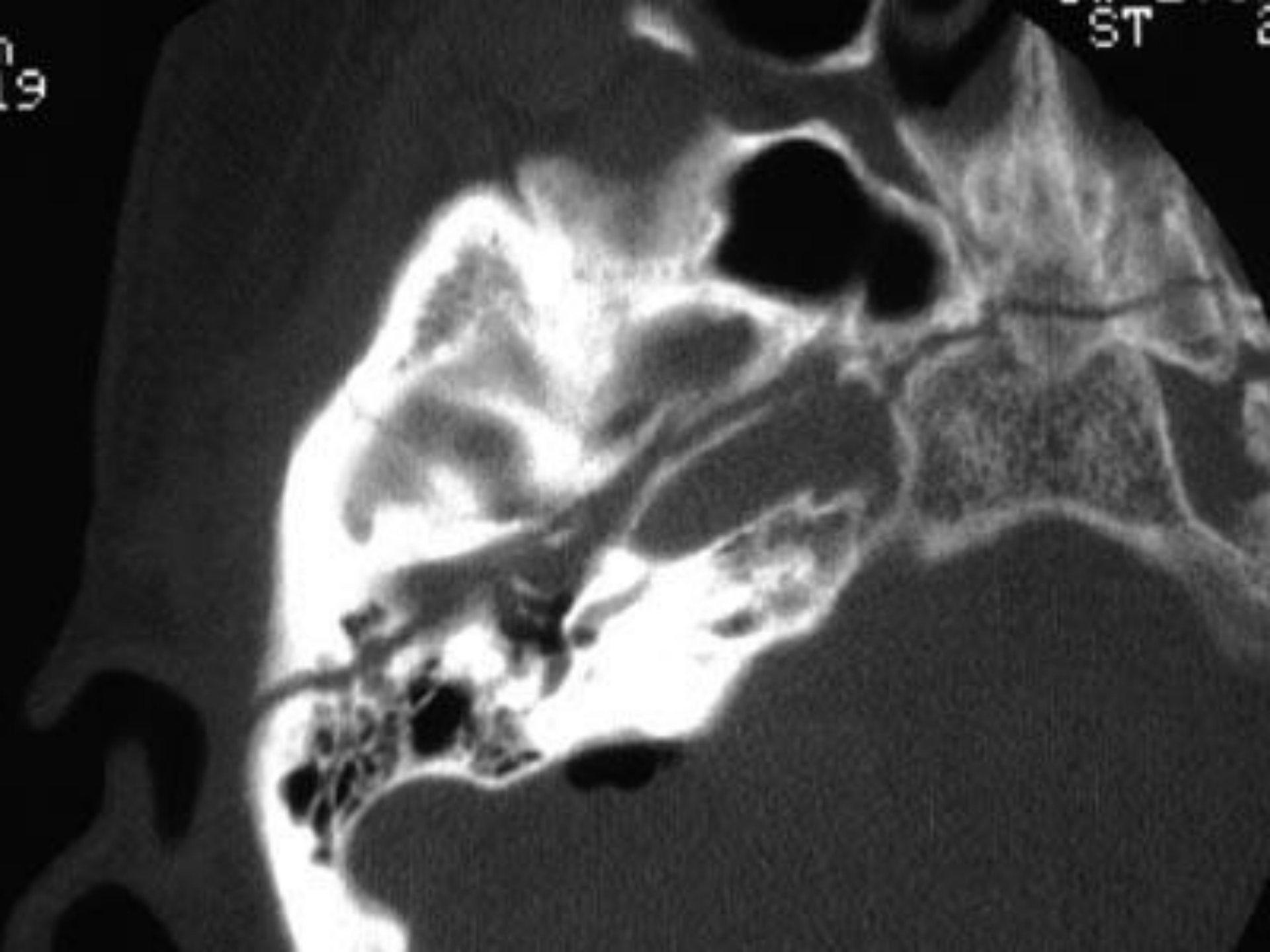
ST

Longitudinal fracture

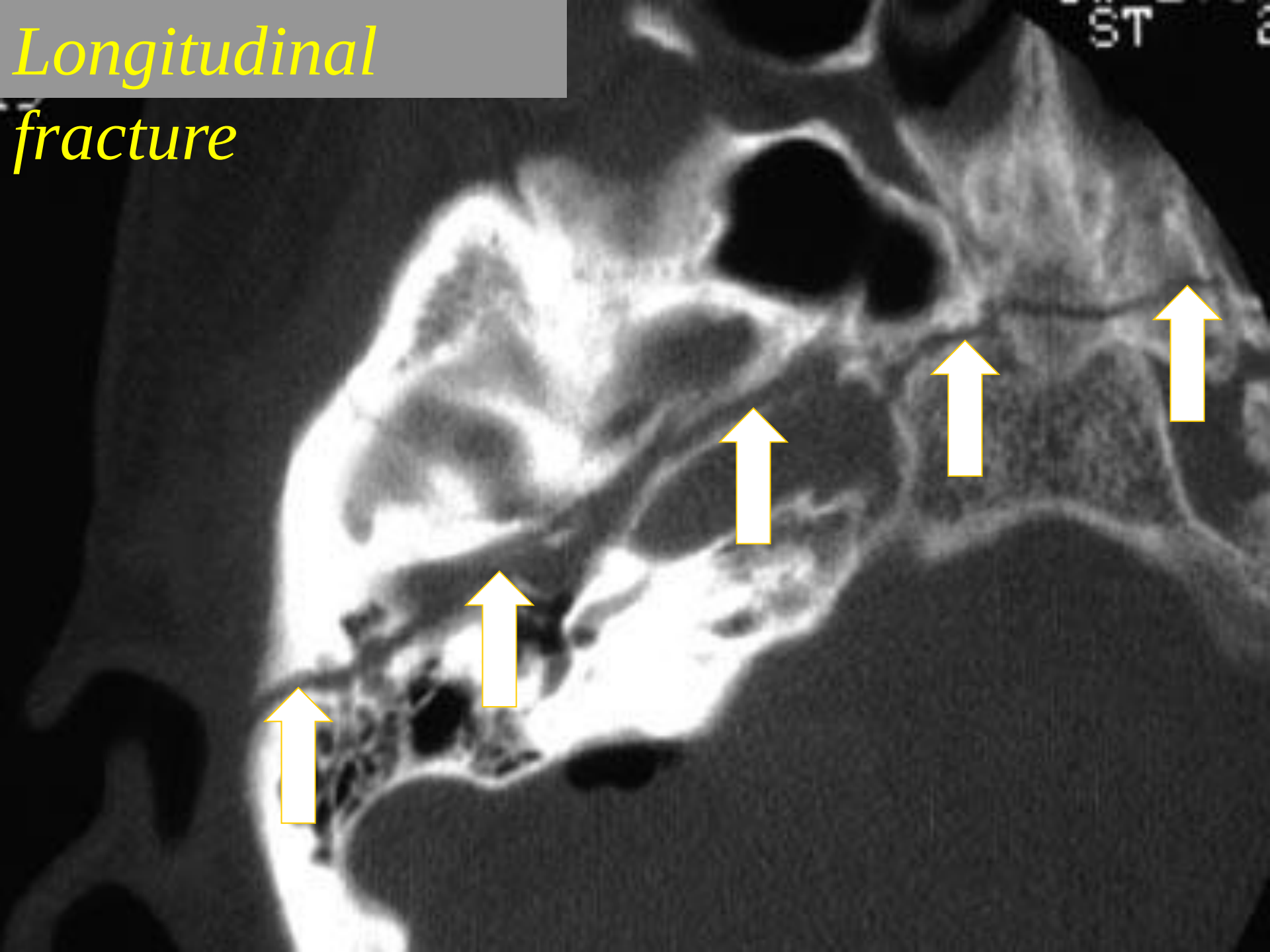

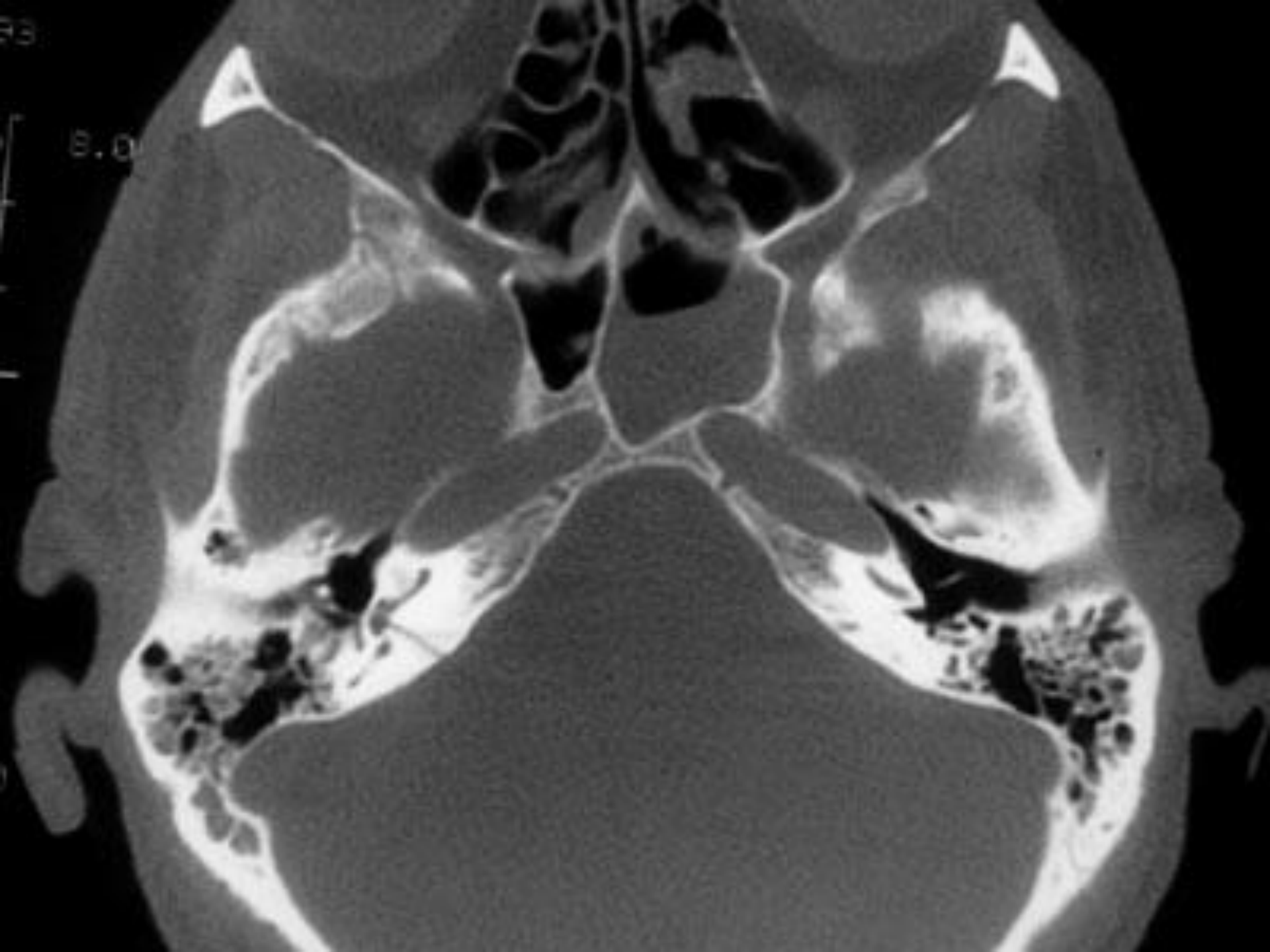
R3
3.0

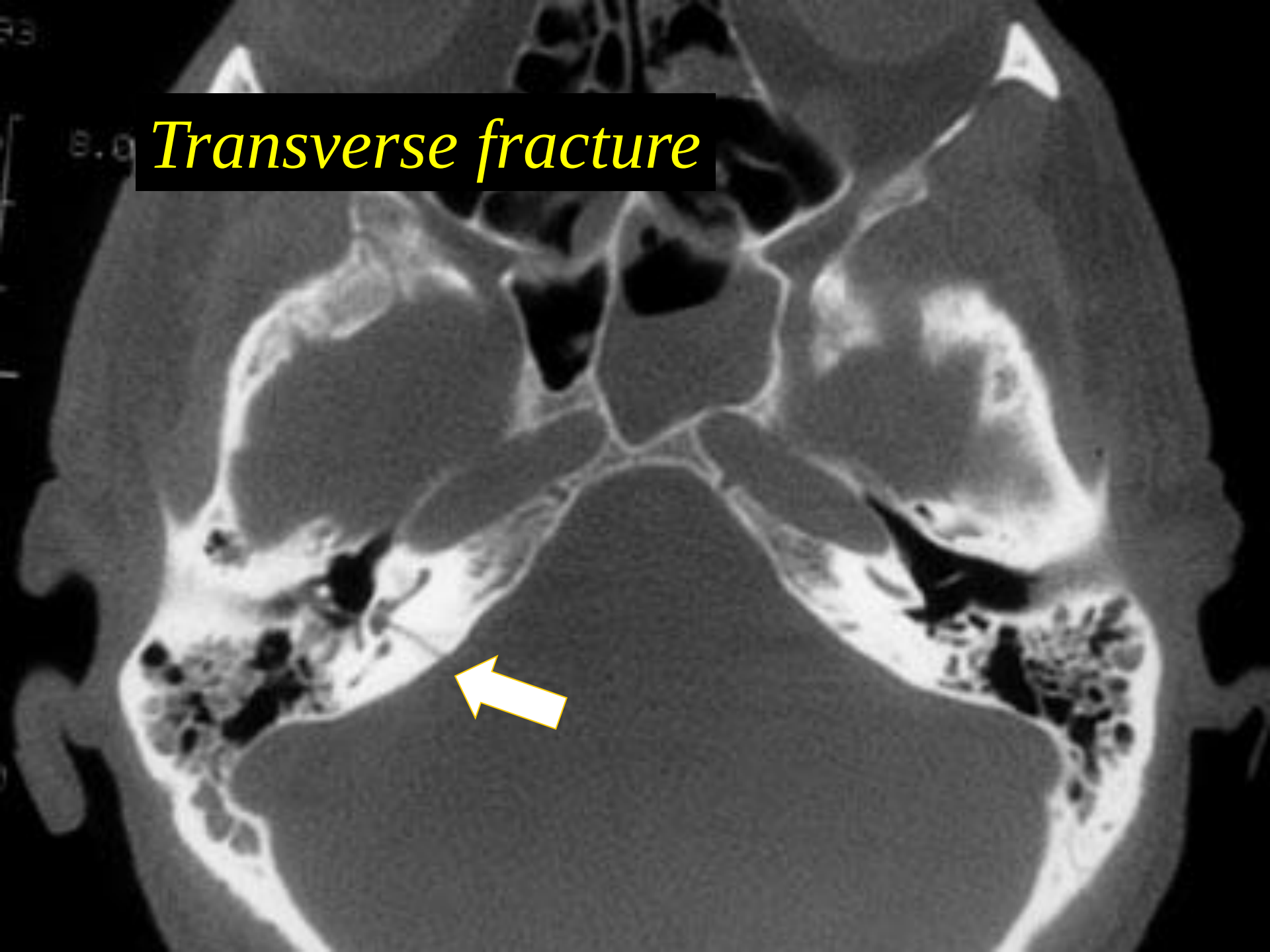
Transverse fracture

Narrow IAC

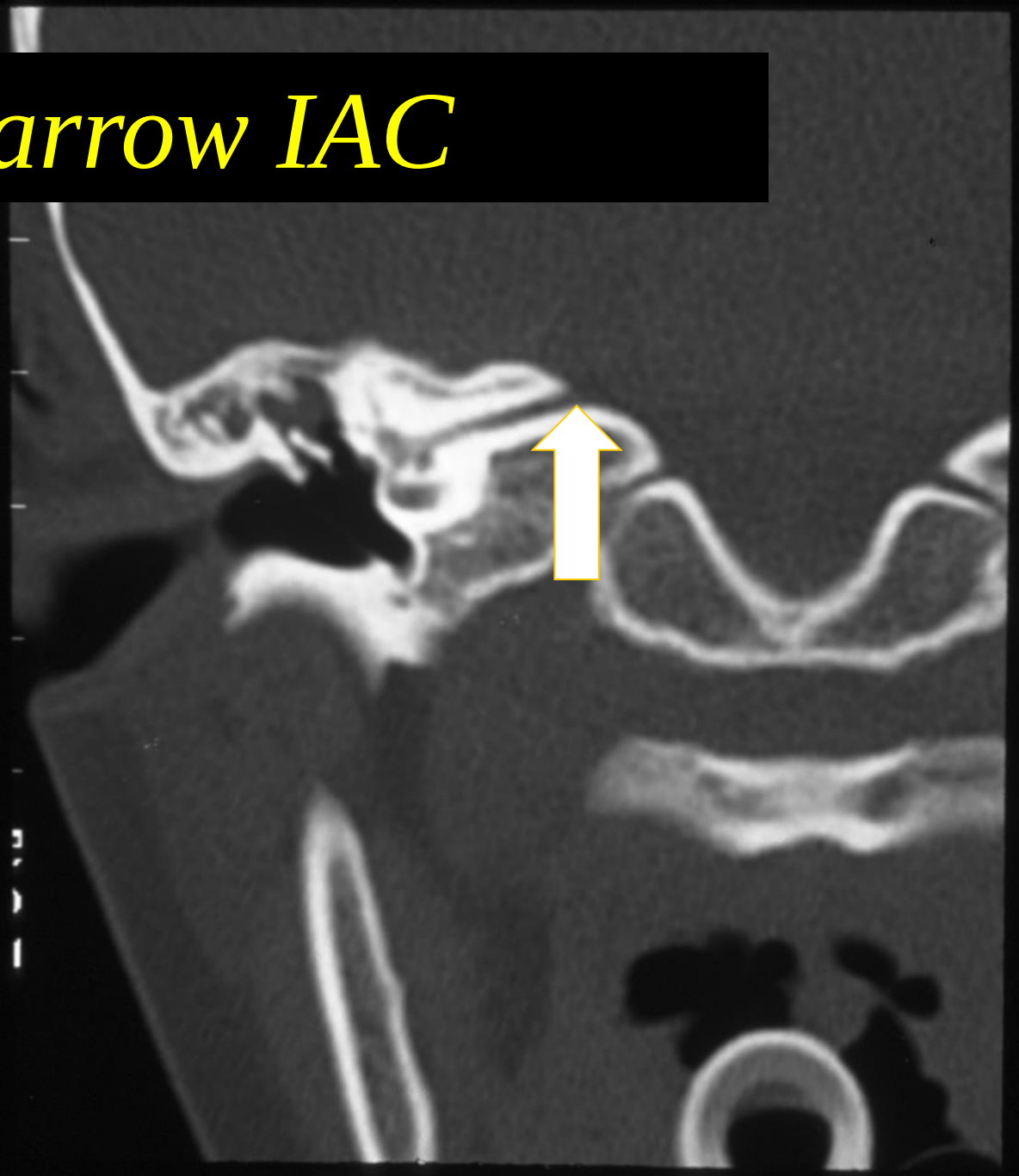

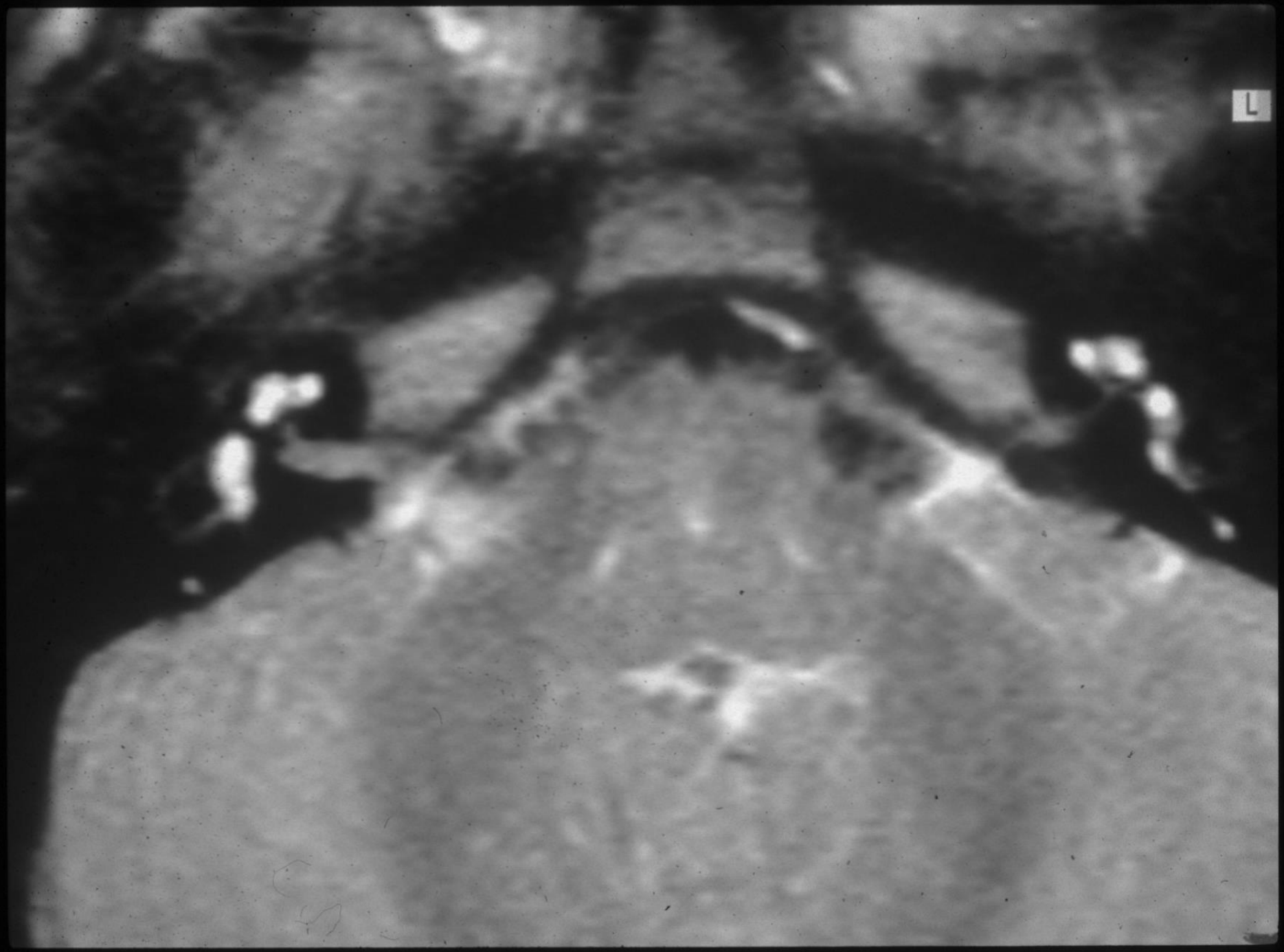
L

Three Dimensional MRI (CISS)

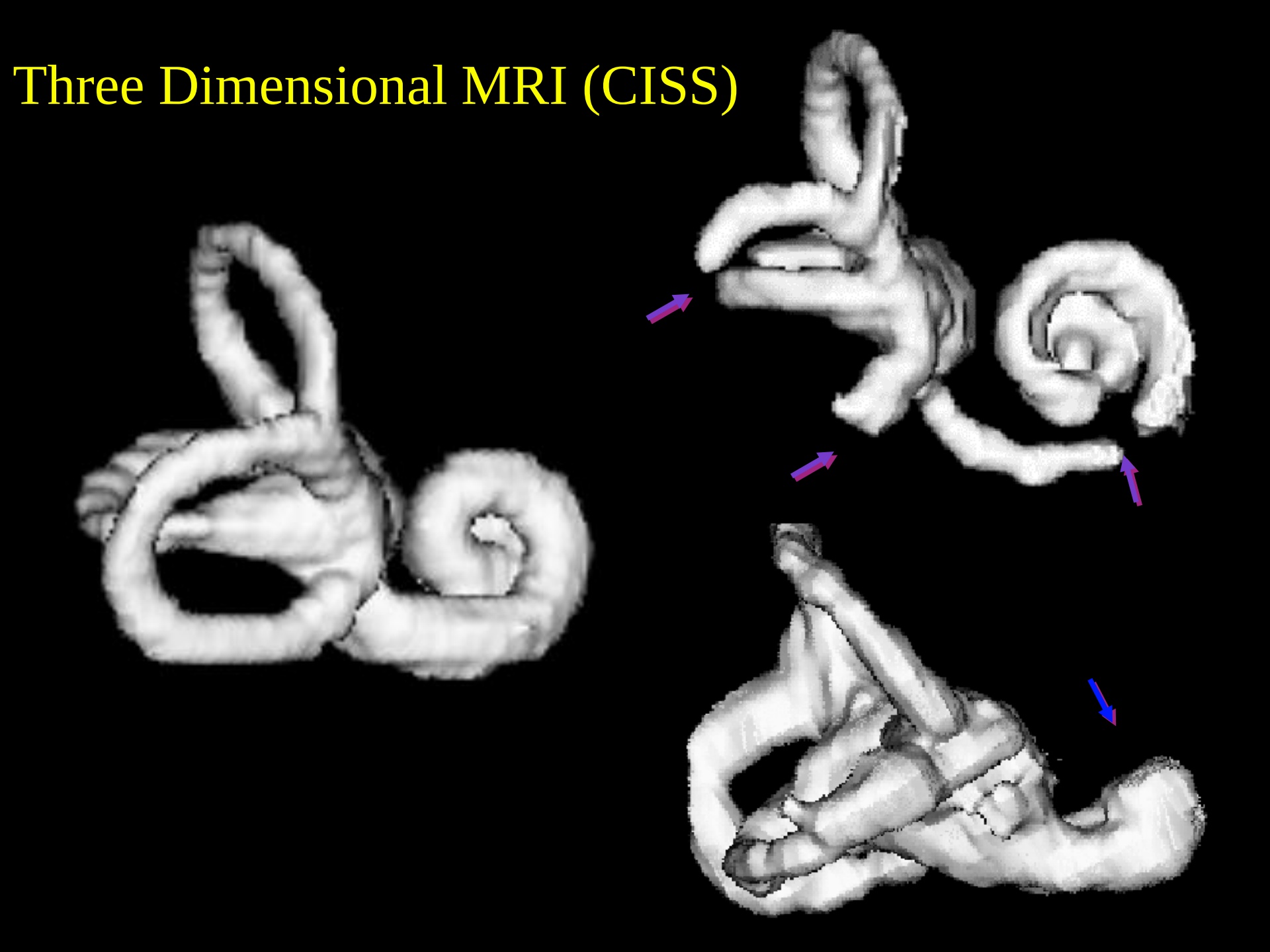

Three Dimensional MRI (CISS) Internal Auditory Canal

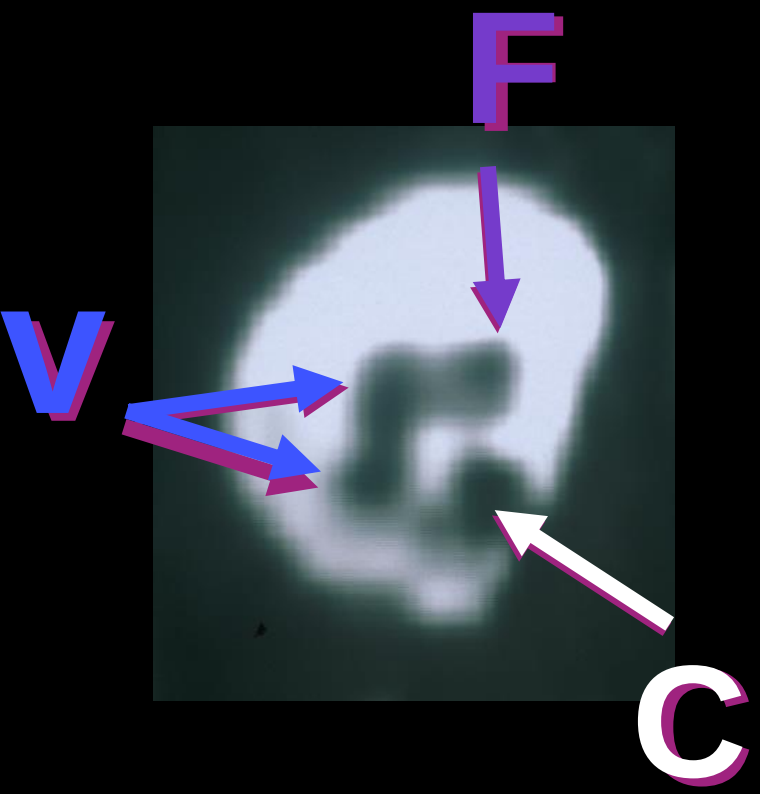

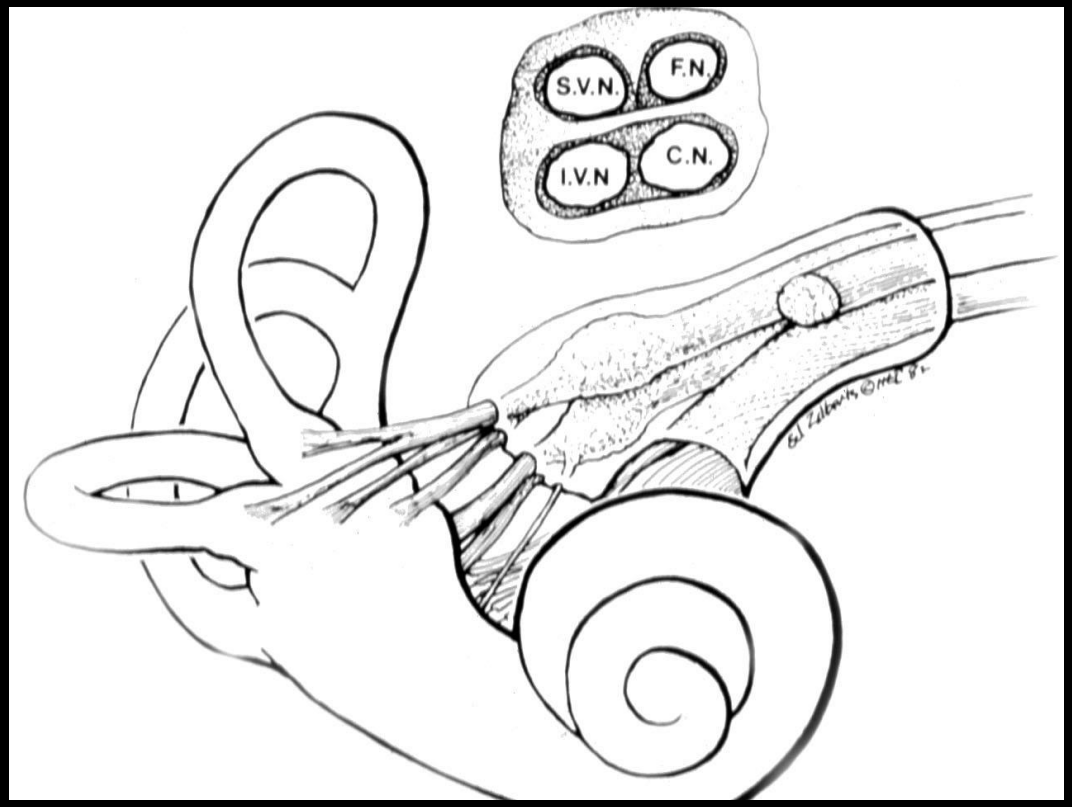

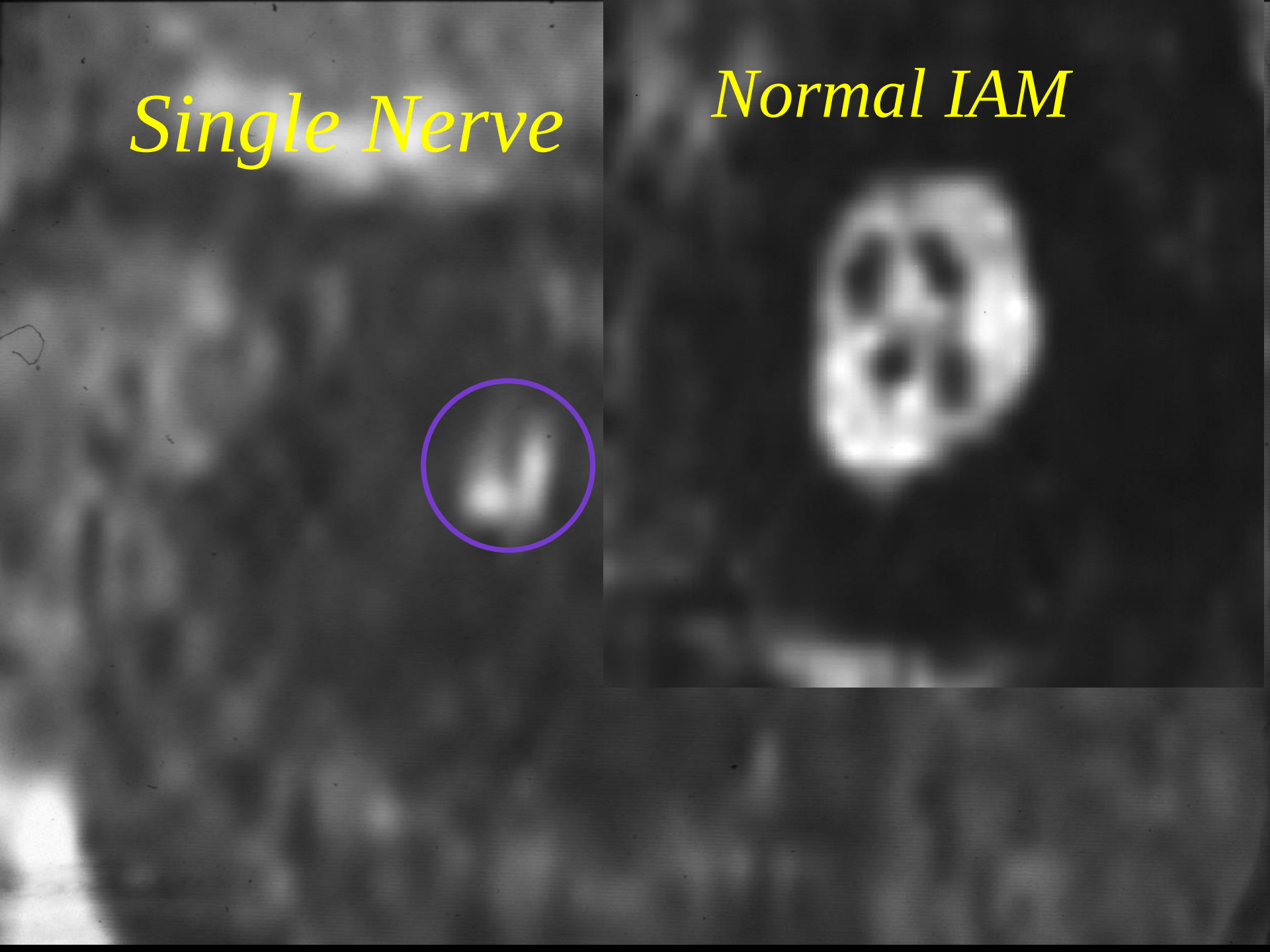
Single Nerve
Normal IAM

Επεμβαση – κλασσικη τομη

Νεα ελαχιστου μηκους τομη

New Minimally invasive approach
O'Donoghue and Nikolopoulos, Otol Neurotol 2002

Ακουστικη αντιληψη προγλωσσικων κωφων παιδιων μετα το εμφυτευμα

CATEGORY OF PERFORMANCE	PRE	1 Y	2Y	3 Y	4 Y	6Y
7. USE OF TELEPHONE – KNOWN SPEAKER	0%	1%	9%	23%	30%	37%
6. UNDERSTAND CONVERSATION WITHOUT LIP-READING	0%	9%	24%	50%	68%	81%
5. UNDERSTAND COMMON PHRASES – NO LIP-READING	0%	37%	73%	93%	96%	100%
4. DISCRIMINATION OF SPEECH SOUNDS	1%	91%	96%	99%	100%	100%
3. IDENTIFICATION OF ENVIRONMENTAL SOUNDS	3%	98%	100%	100%	100%	100%
2. RESPONSE TO SPEECH SOUNDS (e.g. go)	10%	100%	100%	100%	100%	100%
1. AWARENESS OF ENVIRONMENTAL SOUNDS	17%	100%	100%	100%	100%	100%
0. NO AWARENESS OF ENVIRONMENTAL SOUNDS	83%	0%	0%	0%	0%	0%

ΓΟΝΕΙΣ ΚΑΙ ΕΜΦΥΤΕΥΜΑ

Nikolopoulos et al. Arch Otolaryngol Head Neck 2001

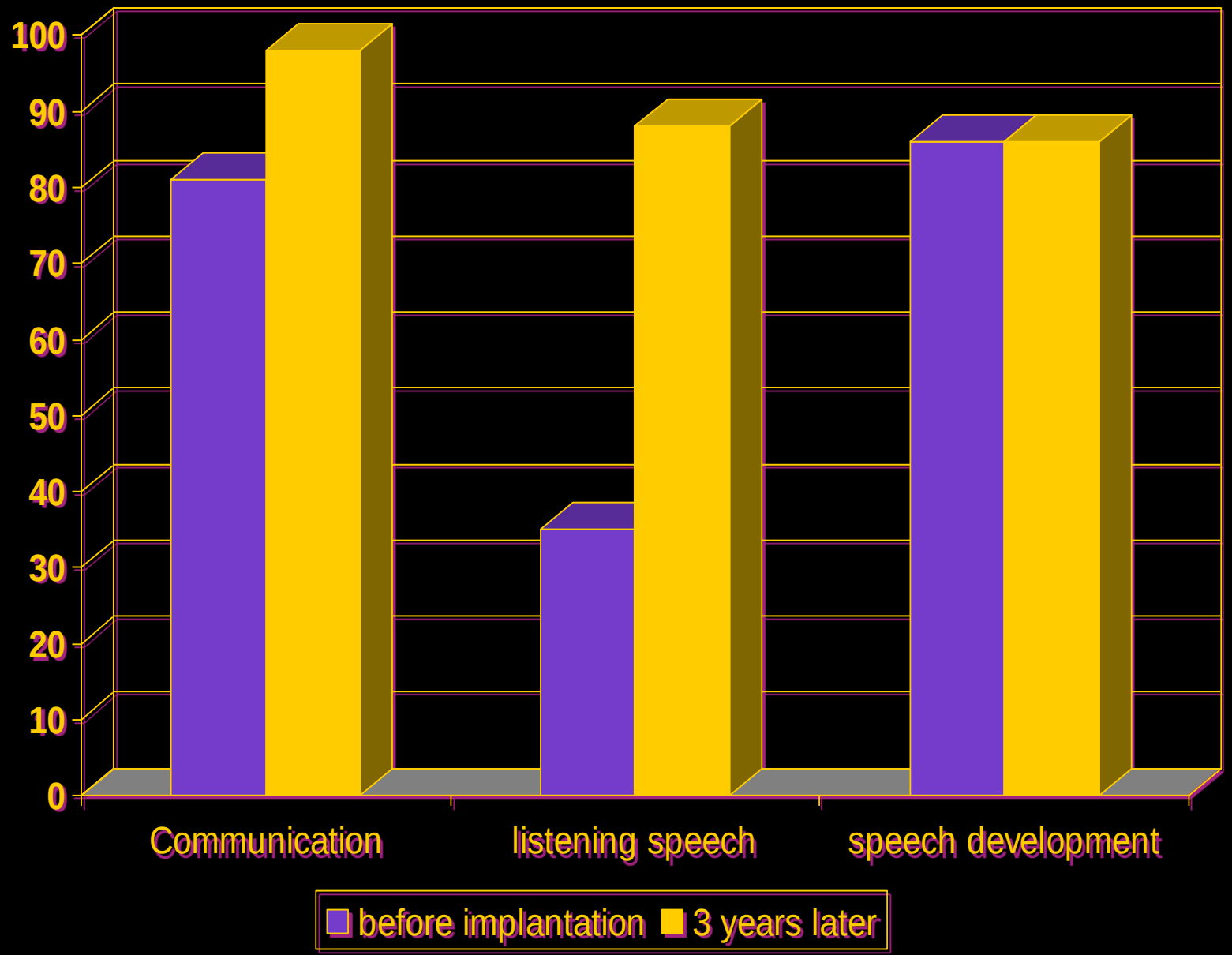

Η ΕΠΕΜΒΑΣΗ ΈΙΝΑΙ ΜΟΝΟ Η ΑΡΧΗ….

Η ΟΜΑΔΑ ΚΟΧΛΙΑΚΩΝ ΕΜΦΥΤΕΥΜΑΤΩΝ

- Ωτοχειρουργος
- Ακοολογος
- Ακτινολογος
- Τεχνικος
- Δασκαλος κωφων
- Λογοθεραπευτης
- Ψυχολογος
- Κοινωνικος Λειτουργος
- Αλλες ειδικότητες

Αλλα…..καθ’ ολη τη διάρκεια…

- Μην ξεχναμε το παιδι και την οικογενεια…
- Συνεχη υποστηριξη

ΤΟ ΜΕΛΛΟΝ....?

- ΠΡΟΛΗΨΗ ΒΑΡΗΚΟΙΑΣ - ΑΜΕΣΗ ΑΝΙΧΝΕΥΣΗ ΒΑΡΗΚΟΙΑΣ - ΕΜΦΥΤΕΥΣΗ ΜΕ ΠΛΗΡΩΣ ΕΜΦΥΤΕΥΟΜΕΝΕΣ ΣΥΣΚΕΥΕΣ - ΑΝΑΓΕΝΝΗΣΗ ΤΡΙΧΩΤΩΝ ΚΥΤΤΑΡΩΝ - ΓΟΝΙΔΙΑΚΗ ΘΕΡΑΠΕΙΑ